

How to manage Ebstein's Anomaly in Pregnancy: A Literature Review with Case Study

Alireza Nematollahi¹, MD;
Shadi Zamansaraei², MD;
Farima Safari³, BSc;
Parvin Bahrami⁴, MD

¹Department of Internal Medicine,
School of Medicine Al-Zahra Hospital
Isfahan University of Medical Sciences,
Isfahan, Iran

²Department of Obstetrics and
Gynecology, Isfahan University of
Medical Sciences, Isfahan, Iran

³Student Research Committee, Shiraz
University of Medical Sciences, Shiraz,
Iran

⁴Department of Cardiology, Alzahra
University Hospital, Isfahan University
of Medical Science, Isfahan, Iran

Correspondence:

Parvin Bahrami, MD;
Department of Cardiology, Alzahra
University Hospital, Isfahan University
of Medical Science, Soffeh Blvd, P.O.
Box: 81746-75731, Isfahan, Iran
Tel: +98 9131941680

Email: parvinbahrami194@gmail.com

Received: 01 April 2022

Revised: 14 May 2022

Accepted: 02 June 2022

Abstract

Background: Ebstein's anomaly (EA) is a congenital heart defect that causes cyanosis and arrhythmia. The treating physician has difficulty when it comes to pregnant women since patients frequently reach reproductive age. How to manage these patients during pregnancy or approach patients who are planning to become pregnant is an important issue. The aim of this study was to evaluate previous and current literature reviews, as well as case studies, to better understand how to treat Ebstein's abnormality in pregnancy.

Methods: This study is a literature review with case report. Here, we review the literature on this subject to discuss how to manage Ebstein's anomaly in pregnancy. We analyzed the literature from different perspectives. We also focused on three of Ebstein's anomaly-affected women's pregnancies.

Results: Three women had four pregnancies, all of which were delivered vaginally or through cesarean section. There were no preterm births. 2.540.88 kg was the average birth weight. There were no cardiac abnormalities in any of the three infants. One patient had Ebstein's abnormality and congenitally corrected transposition of the great arteries (ccTGA).

Conclusion: In Ebstein's abnormality, pregnancy is often well tolerated. However, the maternal risks of pregnancy correlated with the severity of anatomical malformations and the presence of cyanosis or simultaneous other cardiac anomalies.

Please cite this article as: Nematollahi AR, Zamansaraei S, Safari F, Bahrami P. How to manage Ebstein's Anomaly in Pregnancy: A Literature Review with Case Study. *J Health Sci Surveillance Sys.* 2022;10(3):380-387.

Keywords: Ebstein's anomaly, Pregnancy, Congenital heart defect, Cardiovascular abnormality, Cardiovascular disease

Introduction

Ebstein's anomaly (EA) is an uncommon congenital deformity that affects 1-5 out of every 20,000 newborns and accounts for 1% of all congenital heart disease occurrences.¹ The improperly formed and apical displacement of the septal and posterior tricuspid leaflets are the hallmarks of the illness, resulting in tricuspid valve regurgitation and right atrial and functional right ventricular dilatation, which worsens as tricuspid regurgitation (TR) worsens. In EA, nearly half of all afflicted fetuses die in gestation or shortly after delivery owing to the right ventricular failure, while other newborns may require early surgery.² However, in milder types of EA, symptoms (mostly arrhythmias) may

not appear until maturity, or even during pregnancy.³

Physiological alterations in these patients during pregnancy may have negative hemodynamic effects. High-grade TR, right ventricular dysfunction, cerebral abscesses, paradoxical embolism, pulmonary embolism, tachyarrhythmias, sudden cardiac death, and infective endocarditis are some of the problems that might occur during pregnancy.⁴ In the adult population, there are rare cases of L-TGA linked with Ebstein's abnormality, according to the literature. Given that the majority of patients have aortic arch abnormalities, they die within the first few years of life, if not surgically corrected.⁵

Here, we present three different cases with

Ebstein's anomaly in pregnancy which have different features of this anomaly; we aim to describe how to manage EA in pregnancy. Also, an interestingly rare case of a pregnant patient with L-TGA with Ebstein's anomaly was present that decided to continue her pregnancy.

Methods

This study is a literature review with case report. The researchers used an extensive exploration and review of the management of Ebstein's anomaly in pregnancy; recent and current medical research studies and case studies were used to collect quantitative and qualitative data about the management of Ebstein's anomaly in pregnancy used in the past and recent cases. The study included pregnant women with Ebstein's disorder who referred to the prenatal clinic with apical septal leaflet displacement (more than 8 mm is deemed substantial), dilated right heart chambers, reduced contractility, and tricuspid regurgitation between 2019 and 2020. The records for cases 1, 2, and 3 were examined retrospectively for details on the pregnancy's progress and outcome. All patients had a thorough cardiac and obstetric examination before being planned and monitored in the Cardio-Obstetric Clinic. Antenatal care was provided by the policies of the clinic. In the first and second trimesters, the patients were called every two weeks for a follow-up, and in the third trimester, they were contacted every three weeks. The patients were called weekly. The women were assessed by an obstetrician and a cardiologist during their follow-up visits to the clinic. The growth of the fetus was monitored using serial ultrasonography, and growth-delayed fetuses were monitored using a biophysical profile. Patients were admitted to the hospital if they experienced a pregnancy problem, were in labor, or needed to end their pregnancy for whatever reason. Cesarean section was performed only for obstetric reasons.

Continuous cardiac monitoring for the heart rate, arterial blood gas measurement for oxygen saturation, and periodic blood pressure and clinical cardiac evaluation for heart failure were all performed

during labor. As a result, rich data on how to manage Ebstein's anomaly in pregnancy was gathered through integrative and extensive literature and case studies in the past and present to explore how to manage Ebstein's anomaly in pregnancy and improve it.

Results

During the research period, three pregnant women with Ebstein's abnormality were seen at the Clinic (Tables 1 and 2).

Case 1

A 33-year-old Gravidity 1 and Parity 2 at 24 weeks' gestation was referred to the joint clinic for pregnancy and cardiac disease, due to exertional dyspnea and palpitation. Her first pregnancy was at the age of 19. It was terminated by vaginal delivery without any history of maternal or neonatal complications during and after pregnancy (based on the patient's history). However, at about 20-23rd weeks of a second pregnancy, she had dyspnea and had sporadic prenatal visits throughout her pregnancy, but the whole antenatal time was unremarkable. On the evaluation of the cardiovascular system, a split S1 with audible S2 was detected. On the left sternal boundary, a pan systolic murmur was also noted. Right axis deviation with normal sinus rhythm was seen on the ECG, with no evidence of accessory pathways or AV block. Apical displacement of the septal the leaflet of the tricuspid valve, dilated right atrium and right ventricle, mild tricuspid regurgitation, systolic PAP (25mmhg), normal right ventricular function, and a left ventricular ejection fraction of 60% were seen on echocardiography. The diagnosis of Ebstein's abnormality was confirmed by echo results. At the age of 37 weeks in the second pregnancy, she was admitted because of developing rapid weight gain and systemic blood pressure of 145.80 mmHg. The laboratory tests indicated mild preeclampsia. Vaginal delivery was planned for termination, but fetal monitoring revealed fetal distress; therefore, a cesarean section was performed. The neonate was born with a normal

Table 1: Maternal features in the study of Ebstein's anomaly in pregnancy

Case Number.	Age	Age at diagnosis of heart disease	Obstetric history	Echocardiography Diagnosis	Functional Class (NYHA)
1	33	22	G1 P2	Ebstein's anomaly	I
2	25	17	G 0	Ebstein's anomaly no ASD	II- III
3	24	15	G 1	Ebstein's anomaly	II

Table 2: Perinatal outcomes in the study of Ebstein's anomaly in pregnancy

Case Number.	Time to visit the clinic (Weeks gestation)	Cardiac manifestation during pregnancy	Birthweight (gm)	Apgar scores	Type of delivery
1	24	Murmur on left sternal border	3300	10	Vaginal delivery
2	22	Mild LV	2500	9-10	Cesarean section
3	12	cctTGA	2300	10	Cesarean section

Apgar score and a weight of 3.300 kg. The patient was discharged in excellent health three days following the termination, and follow-up appointments were scheduled for six weeks after birth.

Case 2

A 25-year-old woman with Gravidity 0 and Ebstein's abnormality was referred to our pregnancy and heart disease joint clinic for pre-pregnancy counselling. She was diagnosed with Ebstein's anomaly 8 years ago due to dyspnea on exertion. A split S1 was heard with audible S2, S3, and S4 on the cardiovascular system testing. There was also a systolic murmur. The patient had NYHA functional class 1, without any history of syncope or systemic emboli. CXR (Figure 1) and ECG were performed. Right axis deviation was detected on the ECG with a normal sinus rhythm.

The echocardiogram showed mild LV systolic dysfunction (LVEF: 45-50%), abnormal septal motion, severe RA enlargement, severe RV enlargement with moderate to severe systolic dysfunction, apical displacement of posterior TVL (3.5 cm), FAC: 32%, functional RV/anatomical RV=43%, apical displacement of STVL & PTVL, severe TR, TRG: 25 mmHg, and sPAP: 30mmHg (Figures 2, 3, 4).

The exercise stress echocardiography which was performed with bruce protocol revealed no specific ST-T change in comparison with baseline ECG and no arrhythmia on ECG monitoring during stress test with good functional capacity (Mets: 13, duration=10'.30"). Termination of the test was done due to dyspnea and fatigue in stage 4 after the achievement of 90% of maximum HR (MHR: 178bpm). There was a decreased O₂ saturation at peak exercise (94% at baseline decreased to 78% after exercise). Transesophageal echocardiography (TEE) was performed for evaluation of the right to left shunt, showing mild systolic dysfunction (EF: 45-50%), severe RA and RV enlargement with moderate to severe systolic dysfunction, apical displacement of the posterior TVL (4.1 cm), normal IVC size, and >50% respiratory collapse, stretched PFO (7mm) with bidirectional shunt, many bubble passages by contrast study to LA, and no ASD. According to TEE findings, Cardiac Magnetic Resonance (CMR with CHD protocol) was done mainly to determine the severity of the right ventricular dysfunction.

CMR impression: TV Ebstein anomaly with an apical displacement of TV septal leaflet (37.5mm/m2) and severe TR, no TS.

Moderate functional RV enlargement with mild reduced systolic function, functional RVEF: 42%. Severe anatomical RV enlargement with mildly reduced systolic function.

Anatomical RVEF: 44%. RV functional/anatomical

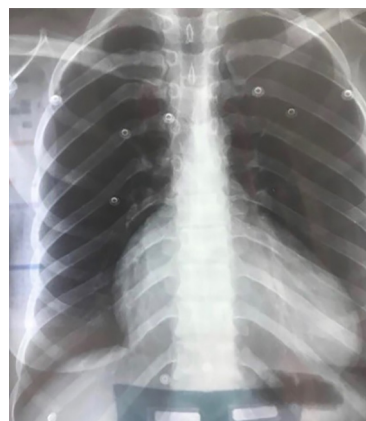

Figure 1: Posteroanterior chest X-ray

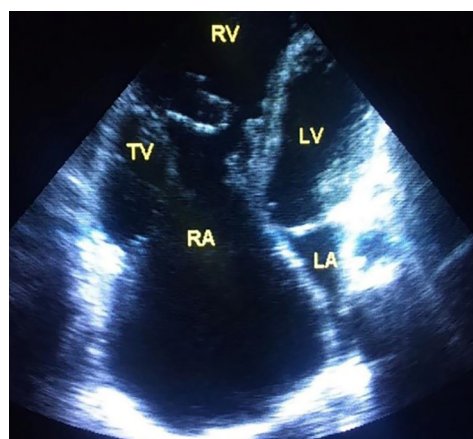


Figure 2: Two-dimensional echocardiography apical 4 chamber view Ebstein anomaly of the tricuspid valve

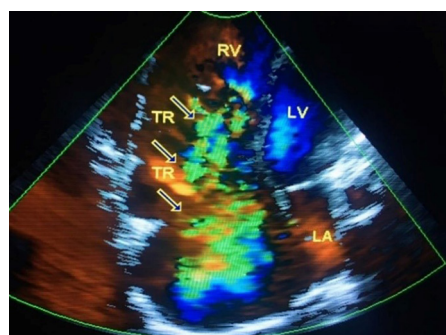


Figure 3: Color Doppler echocardiography Apical 4 chamber view revealed Tricuspid regurgitation

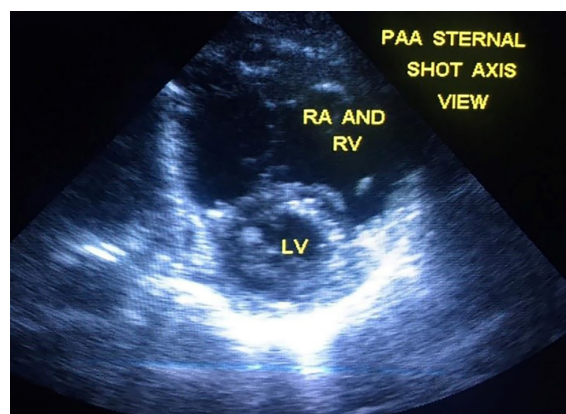


Figure 4: Parasternal short-axis view revealed Right Ventricular Enlargement in Ebstein anomaly

area ratio in 4CH view 30%. RV functional/anatomical 3D volume ratio=45%.

Normal LV size and systolic function (LVEF=53%).

Recommendation: since she was not a suitable candidate for TV repair, Holter monitoring was performed which showed no arrhythmia.

The patient was considered as m-WHO class II-III. Echocardiography was performed again during pregnancy which did not reveal a significant change. The pregnancy was carried to term, and a cesarean section was performed at week 38 owing to the patient's desire and to avoid protracted induction of labor. A female neonate with Apgar 9-10 was born with a normal general appearance weighing 2.5 kg. The patient was discharged on the third surgical day with instructions to follow up with a postnatal clinic and cardiologist appointment in one month.

Case 3

At 12 weeks' gestation, a 24-year-old Gravity 1 presented to the joint clinic for pregnancy and heart illness. During childhood, the patient had been diagnosed with congenitally corrected transposition of the great arteries (ccTGA) and Ebstein's abnormality of the systemic AV valve. Throughout the first trimester of pregnancy, the patient remained in NYHA class II. Although the visceral and vestibular position is single and normal and there was no situs inversus, the echocardiography shows that the ventricular atrial (AV) connection and the ventricular connection with the large arteries and ventricular arteries (VA) are uncoordinated and discordant; also, the ventricles are displaced (L-malpositioned or L-Loop); the right ventricle is morphologically in the left side, and the left ventricle is morphologically in the right side. The systemic ventricle which was here morphologic RV had moderate to severe enlargement (RV-EDDI=6.7cm) with moderate systolic dysfunction (RV-EF=35%). This sub-aortic ventricle also had Ebstein's anomaly in systemic atrioventricular valve and tricuspid valve (TV) displacement which was 3.1cm. TV had a significant tricuspid regurgitation (TR) but

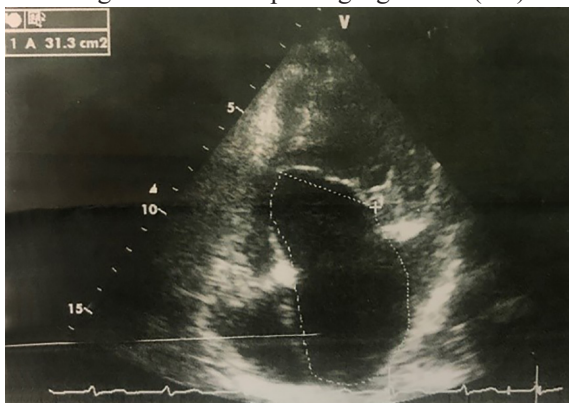


Figure 5: Two-dimensional echocardiography apical four chamber view revealed Ebstein anomaly in tricuspid valve in congenitally corrected transposition of a great vessel

no tricuspid stenosis (TS). Moreover, the aorta was placed anterior to and at the left side of the pulmonary artery, and its valve had mild aortic insufficiency (AI). The left atrium showed severe enlargement, while the size of the right atrium was normal. On the right side, morphologic LV had normal size and preserved the systolic function and just the pulmonary valve seemed bicuspid with mild pulmonary insufficiency (PI) in the echocardiography. Besides, the mitral valve which was on the right side was normal with trivial mitral regurgitation (MR) and no stenosis. The patient also did not have any ventricular septal defect (VSD) (Figures 5, 6).

Reduced function of the systemic ventricle (which is morphologic RV) was verified on echocardiography, along with Ebstein's abnormality in the systemic AV valve, and the woman was advised to have a therapeutic abortion, which she rejected. Thus, the patient was followed up and checked regularly for detection of the symptoms of heart failure and arrhythmia. Because her systemic ventricle EF was poor, the patient was additionally given low molecular weight heparin, Enoxaparin 40mg daily (at the preventive dosage), and a beta-blocker, Bisoprolol 2.5 mg daily. The patient was prescribed Aspirin to prevent pregnancy-induced hypertension (PIH). Moreover, Brain natriuretic peptide (NT-pro BNP) was tested every trimester for prognostic value and prediction of adverse cardiac events and life-threatening maternal complications during pregnancy. The level of NT-pro BNP at the beginning of pregnancy, the end of the first and second trimester was 180pg/ml, 185, and 230 respectively, and the patient was visited every 2 weeks during the third trimester. Moreover, fetal echocardiography at the 18th week of pregnancy revealed no obvious congenital heart anomaly.

At the onset of the 36th week of pregnancy, the patient was admitted for palpitations and dyspnea on exertion. Level of NT-pro-BNP was checked. Based on these symptoms with 92% O₂ saturation in room air, in addition to an increased level of NT-pro BNP (up to 330 pg/ml), hospitalization and cesarean section

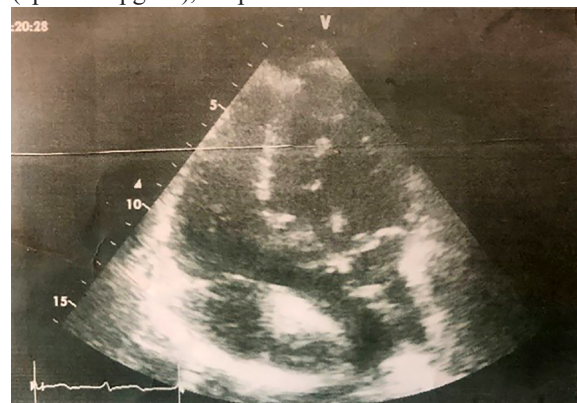


Figure 6: Apical five chamber view in congenitally corrected transposition of great vessels

were decided. Her baby was born with a normal Apgar score and weight of 2.3 kg. The patient was discharged on the seventh postoperative day after the sutures were removed, and she was prescribed Bisoprolol and the ACE inhibitor Enalapril 2.5 mg twice a day, with the recommendation that she return to the postnatal joint clinic in two weeks.

Discussion

The main concepts necessary for optimal management of Ebstein's abnormality in pregnancy have been explained in this article through a literature review and a supporting case study. In many cases, Ebstein's abnormality is a congenital tricuspid valve deformity with extra involvement of the RV myocardium and outflow tract. In women with Ebstein's abnormality, the volume burden of pregnancy can lead to cardiac problems.⁶ During pregnancy, the majority of women perform well. In patients who survive to adulthood and childbearing age without severe symptoms, pregnancy is considered feasible, but some symptomatic patients may face different complications during pregnancy as a result of physiological changes and elevations in the circulating catecholamine concentrations. These significant physiological changes impose a great burden on the circulatory system of the patients with EA which can be life-threatening.^{7, 8} The apical displacement of the septal leaflet, which is deemed severe if larger than 8 mm (our case 1 had 18 mm displacement), dilated right heart chambers, reduced contractility, and related abnormalities can all be seen on 2-D echocardiography.⁹

Tricuspid regurgitation may worsen when circulatory volume and preload rise, causing cardiac chamber dilatation. Elevated right atrial pressure may also affect the degree of interatrial shunting, resulting in cyanosis, right heart failure, and left diastolic heart failure.^{10, 11} Elevated circulating catecholamine concentrations can lead to a risk of arrhythmias, which is the most prevalent consequence. In individuals with ASDs or PFO, the Valsalva maneuver during delivery may cause an interatrial right-to-left shunt, increasing the risk of a paradoxical embolus.¹² To predict cardiac problems during pregnancy, the modified World Health Organization risk classification,¹³ the CARPREG risk score,¹⁴ and the ZAHARA risk score¹⁵ might be utilized. Furthermore, the NYHA functional class of >II, cyanosis or previous arrhythmia episodes are linked to poor pregnancy outcomes. In the biggest research on the outcome of pregnancies in moms with EA, 44 women participated in 111 pregnancies, with 85 live babies (76 per cent). The majority of women had EA that had not been addressed. Sixteen women were cyanotic during pregnancy owing to interatrial shunting, and five had supplementary conduction channels. There were 23 preterm births, as well as 19 spontaneous miscarriages (17%), 7 therapeutic abortions, and two early neonatal

deaths. There were no significant pregnancy-related complications for the mother.¹⁶

As a result, pregnant patients should be constantly monitored, with appropriate treatments carried out depending on the severity of their problems. In women with various forms of cardiac disease, higher rates of poor fetal outcomes, particularly low birth weight and preterm, have also been documented in the literature.¹⁷ Cyanosis and low cardiac output are the risk factors for poor fetal outcomes. In EA patients, cyanosis and the requirement for anticoagulation are prevalent; thus, poor fetal outcomes should be addressed. During their pregnancy, EA patients should see a cardiologist who specialist in CHD therapy, as well as an obstetric and cardiac anesthesiologist. The aorta receives oxygen-rich blood from the right ventricle and sends it to other organs, while the pulmonary artery receives oxygen-poor blood from the left ventricle and sends it to the lungs, so the morphologic right ventricle serves as the subaortic ventricle supporting systemic circulation in Cc-TGA.¹⁸

Cardiovascular problems are uncommon in women with a good functional class and normal subaortic ventricular function. During pregnancy, women with significant subaortic right ventricular dysfunction, whether or not they have tricuspid valve regurgitation, are at risk for additional ventricular dysfunction and clinical heart failure. Serial transthoracic echocardiograms are recommended for close monitoring, and arrhythmias should be found and treated quickly.¹⁹ The frequency of follow-up in EA is determined by the maternal heart condition. Pregnancies may frequently be tolerated successfully in low-risk individuals (WHO class II), such as the first example in our research, and they can be examined by a cardiologist every trimester. There is a higher risk of problems for women in WHO class III, such as the third case in our research, so monthly or biweekly cardiology visits are suggested to monitor for changes in their heart condition.²⁰

According to the existing published information on EA in pregnancy, only 3% of these individuals had heart failure.²¹ NYHA class III, m-WHO pregnancy class III, prior cardiomyopathy, preexisting pulmonary hypertension, and preexisting symptoms of heart failure were all linked with heart failure in EA.²² The detection of natriuretic peptides (pro-BNP or BNP) in these individuals can help risk-stratify them. Normal BNP levels (100-128 pg/ml) at 20 weeks of pregnancy were reported to have a 96 per cent-100 per cent negative predictive value for heart failure events linked to pregnancy. Patients with high BNP levels at 20 weeks of pregnancy had a greater risk of heart failure.^{23, 24} In the care of EA with high-risk features, a thorough examination for hypoxia and cyanosis is required. Supplemental oxygen may be explored in individuals with cyanosis.

Cardiac output should be maintained by preventing dehydration and thromboembolic events should be avoided. The physiologic range for hematocrit should be maintained.²⁵

Early delivery is possible for women with moderate EA. Individual decisions should be taken for patients with problems such as arrhythmia, cardiac failure, or increasing cyanosis. Women with cyanosis, uncontrolled arrhythmias, or unstable hemodynamics should seek elective CS, according to Circulation Society recommendations. Despite the difficulty of objectively evaluating the signs of right heart failure that is defined as Ebstein's abnormality, it is critical to choose the proper route of delivery. The biggest available series demonstrate vaginal birth with epidural analgesia to be safe in EA when choosing the method of delivery.^{26, 27} Women with cyanosis, uncontrolled arrhythmias, or unstable hemodynamics should seek elective caesarian section, according to the Japan Circulation Society recommendations.²⁸ Despite the difficulty of objectively evaluating the signs of right heart failure that is defined as Ebstein's abnormality, it is critical to choose the proper route of delivery.²¹ In this present study, second-case cesarean delivery was done due to obstetrician indication and patient preference. However, in the third case our team decided to perform cesarean delivery under general anesthesia to avoid hemodynamic disturbance since she was at risk for decompensated heart failure.

Asymptomatic or trivial symptomatic patient as the first case in the study may not need additional hemodynamic measures. Women with cyanosis, uncontrolled arrhythmias, or unstable hemodynamics should seek elective cesarean birth, according to Circu-Latin Society recommendations.²⁶ Despite the difficulty of objectively evaluating the signs of right heart failure that is defined as Ebstein's abnormality, it is critical to choose the proper route of delivery. Caesarean section is preferable for some high-risk individuals, such as cyanotic patients who are starting warfarin therapy within two weeks after birth. In the first and second cases, we suggested a hospital stay of at least 48 hours to watch for arrhythmia and other problems, but in the third instance, because heart failure or cyanosis was more possible, she required a longer postpartum hospital stay.²⁹ Although EA is not expressly listed in the WHO classification, individuals can nonetheless be categorized based on their EA symptoms. Patients with cyanosis and another complex congenital heart disease, as well as a poor functional class due to preexisting right or left heart dysfunction, may experience more overt complications such as exacerbation of heart failure symptoms, persistent arrhythmias, and worsening preexisting cyanosis, and are classified as WHO class III, because of the inability to deal with pregnancy higher volume and cardiac output needs.^{30, 31} When an

EA patient decides to get pregnant, she should seek preconception counseling from a cardiologist who is specialist in ACHD. A thorough, cardiac-focused physical examination should be performed, focusing on signs and symptoms of persistent hypoxia, congestive heart failure, arrhythmia, and any other indications of EA systemic manifestations.³² If you haven't had an ECG or transthoracic echocardiography recently, you should get these done. During cardiopulmonary exercise testing, functional capacity and systemic saturation should be evaluated at rest and during activity. The extent of further testing, which may include a cardiac MRI, will be determined by the severity of the illness and the patient's present heart state. Medical therapies such as heart failure and arrhythmia therapy are available.³³ If an auxiliary pathway is available, the latter problem can be treated pharmacologically or by radiofrequency ablation.³⁴

Conclusion

Most women do well during pregnancy. They have a milder form of an anomaly with little right ventricular dysfunction, without cyanosis or symptomatic arrhythmias before pregnancy, so they tolerate pregnancy physiologic changes well (m-WHO II). When a patient with EA decides to get pregnant and there are some findings that the risk of pregnancy is more doubtful, evaluation of the patient with more tests should be considered by the cardiologist expert in congenital malformation in pregnancy. If EA is associated with other concomitant congenital anomaly such as ccTGA, making decision about pregnancy becomes more complicated since clinical experiences in these cases are limited. The nature and severity of the anatomical abnormality, as well as the patient's functional state, all play a role in management.

Implications of the Findings

Patients with complicated congenital heart disease who are pregnant require close follow-up in expert centers. This manuscript provides excellent examples of well-managed patients that may help the clinicians for the approach they should take for these patients, especially in preconception visit.

Highlights

1) EA risk classification in pregnancy should be based on the functional class, oxygen saturation, arrhythmia proclivity, and other factors such as the size and systolic function of the "functional" right ventricle, presence of an interatrial shunt, as well as the degree of tricuspid regurgitation.

2) During pregnancy, management guidelines for clinical surveillance include oxygen saturation,

echocardiographic monitoring of the right ventricular systolic function, and blood pressure monitoring. For interatrial shunt problems, air filters on the intravenous lines are used.

3) Arrhythmias, right heart failure, paradoxical emboli, and oxygen desaturation are also common maternal problems in EA patients.

Ethical Consideration

These case reports in this review article were prepared after getting informed written consent from the patient.

Funding

This study did not receive any funding

Conflicts of interest: None declared.

References

- Sherwin ED, Abrams DJ. Ebstein Anomaly. *Cardiac electrophysiology clinics*. 2017 Jun 1;9(2):245-54.
- Freud LR, Escobar-Diaz MC, Kalish BT et al Outcomes and predictors of perinatal mortality in fetuses with Ebstein anomaly or tricuspid valve dysplasia in the current era: a multicenter study. *Circulation* 2015;132:481–489.
- Safi LM, Liberthson RR, Bhatt A. Current Management of Ebstein's Anomaly in the Adult. *Curr Treat Options Cardiovasc Med* 2016 ;18-56.
- Kanoh M, Inai K, Shinohara T, Shimada E, Shimizu M, Tomimatsu H, Ogawa M, Nakanishi T. Influence of pregnancy on cardiac function and hemodynamics in women with Ebstein's anomaly. *Acta obstetrica et gynecologica Scandinavica*. 2018 Aug;97(8):1025-31.
- Rydzevska K, Sylwestrzak O, Krekora M, Słodki M, Respondek-Liberska M. Ebstein's anomaly: epidemiological analysis and presentation of different prenatal management. *The Journal of Maternal-Fetal & Neonatal Medicine*. 2020 Sep 15:1-8.
- Possner M, Gensini FJ, Mauchley DC, Krieger EV, Steinberg ZL. Ebstein's Anomaly of the Tricuspid Valve: An Overview of Pathology and Management. *Current Cardiology Reports*. 2020 Dec;22(12):1-7.
- Gite JV, Gangakhedkar GR, Nadkarni M. Anaesthetic management of emergency lower segment caesarean section in a patient with Ebstein's anomaly. *Indian journal of anaesthesia*. 2018 Nov;62(11):915.
- Kanoh M, Inai K, Shinohara T, Shimada E, Shimizu M, Tomimatsu H, Ogawa M, Nakanishi T. Influence of pregnancy on cardiac function and hemodynamics in women with Ebstein's anomaly. *Acta obstetrica et gynecologica Scandinavica*. 2018 Aug;97(8):1025-31.
- Torigoe F, Ishida H, Ishii Y, Ishii R, Narita J, Kawazu Y, Kayatani F, Inamura N. Fetal echocardiographic prediction score for perinatal mortality in tricuspid valve dysplasia and Ebstein's anomaly. *Ultrasound in Obstetrics & Gynecology*. 2020 Feb;55(2):226-32.
- Masoller N, Del Rincón OG, Herraiz I, Gómez-Montes E, Soveral I, Pérez-Cruz M, Martínez-Biosques C, Granados MA, Bannasar M, Escobar-Diaz MC, Martínez JM. Prediction of Perinatal Mortality in Ebstein's Anomaly Diagnosed in the Second Trimester of Pregnancy. *Fetal diagnosis and therapy*. 2020;47(8):604-14.
- Wu, Yuduo, Xiaoyan Gu, Yihua He, and Hongjia Zhang. "Echocardiographic Characteristics and Prognosis of the Fetuses with Ebstein Anomaly in Pregnancy." (2020).
- Kanoh M, Inai K, Shinohara T, Shimada E, Shimizu M, Tomimatsu H, Ogawa M, Nakanishi T. Influence of pregnancy on cardiac function and hemodynamics in women with Ebstein's anomaly. *Acta obstetrica et gynecologica Scandinavica*. 2018 Aug;97(8):1025-31.
- Regitz-Zagrosek, V., et al., 2018 ESC Guidelines for the management of cardiovascular diseases during pregnancy: The Task Force for the Management of Cardiovascular Diseases during Pregnancy of the European Society of Cardiology (ESC). *European Heart Journal* 2018 ;39: 3165-3241.
- Siu SC, Sermer M, Colman JM, Alvarez AN, Mercier LA, Morton BC, et al. Prospective multicenter study of pregnancy outcomes in women with heart disease. *Circulation*. 2001;104:515–21.
- Drenthen W, Boersma E, Balci A, Moons P, RoosHesselink JW, Mulder BJ, et al. Predictors of pregnancy complications in women with congenital heart disease. *Eur Heart J*. 2010;31:2124–32.
- Connolly HM, Warnes CA. Ebstein's anomaly: outcome of pregnancy. *J Am Coll Cardiol*. 1994 Apr; 23:1194-8. doi: 10.1016/0735-1097(94)90610-6. PMID: 8144788.
- Kanoh, M, Inai, K, Shinohara, T, Shimada, E, Shimizu, M, Tomimatsu, H, et al. Influence of pregnancy on cardiac function and hemodynamics in women with Ebstein's anomaly. *Acta Obstet Gynecol Scand* 2018; 97: 1025– 1031.
- Possner M, Gensini FJ, Mauchley DC, Krieger EV, Steinberg ZL. Ebstein's Anomaly of the Tricuspid Valve: An Overview of Pathology and Management. *Current Cardiology Reports*. 2020 Dec;22(12):1-7.
- Rydzevska K, Murlewska J, Krekora M, Maroszyńska I, Moll M, Respondek-Liberska M. The attempt of pregnancy modification in a case of fetal Ebstein's anomaly. *Prenatal Cardiology*. 2020;2019(1):56-60.
- Sharma T, Habash F, Mounsey J, Baker C, Candales AL. Ebstein's Anomaly in Disguise: Follow the Cues and the Diagnosis Can Be Made. *Cureus*. 2020 Oct;12(10).
- Drenthen W, Pieper PG, Roos-Hesselink JW et al Outcome of pregnancy in women with congenital heart disease. *J Am Coll Cardiol* 2007;49:2303–2311.
- Ruys TPE, Roos-Hesselink JW, Hall R et al Heart failure in pregnant women with cardiac disease: data

- from the ROPAC. *Heart* 2014; 100:231–238.
- 23 Kampman MM, Balci A, van Veldhuisen DJ et al N-terminal pro-B-type natriuretic peptide predicts cardiovascular complications in pregnant women with congenital heart disease. *Eur Heart J* 2014; 35:708–715 33.
 - 24 Tanous D, Siu SC, Mason J et al B-type natriuretic peptide in pregnant women with heart disease. *J Am Coll Cardiol* 2010; 56:1247–125.
 - 25 Susilowati E. Management of Pregnancy in 31-Year-Old Woman with Persistent Atrial Flutter After Cone Reconstruction for Ebstein's Anomaly. *Cardiovascular and Cardiometabolic Journal (CCJ)*. 2020 Mar 20;1(1):17-25.
 - 26 Holst KA, Connolly HM, Dearani JA. Ebstein's anomaly. *Methodist DeBakey cardiovascular journal*. 2019 Apr;15(2):138.
 - 27 Kochav J. Ebstein's Anomaly of the Tricuspid Valve. In *Adult Congenital Heart Disease in Clinical Practice* 2018 (pp. 371-390). Springer, Cham.
 - 28 JCS Joint Working Group. Guidelines for indication and management of pregnancy and delivery in women with heart disease (JCS 2010): digest version. *Circ J*. 2012; 76: 240– 60.
 - 29 Holst KA, Dearani JA, Qureshi MY, Wackel P, Cannon BC, O'Leary PW, Olson TM, Seisler DK, Nelson TJ, Cavanaugh K, Wobig J. From safety to benefit in cell delivery during surgical repair of Ebstein anomaly: initial results. *The Annals of Thoracic Surgery*. 2021 Feb 1.
 - 30 Elzein C, Subramanian S, Ilbawi M. Surgical management of neonatal Ebstein's anomaly associated with circular shunt. *World Journal for Pediatric and Congenital Heart Surgery*. 2019 Jan;10(1):116-20.
 - 31 Katamreddy A, Thachil R. Ebstein's anomaly in a tachycardic postpartum woman. *Journal of the American College of Cardiology*. 2019 Mar 12;73(9S1):2518.
 - 32 Evans E, McDonald M, Adamson DL, Khan JN. Cardiomyopathy in the peripartum period due to left ventricular non-compaction and association with Ebstein's anomaly: a case report. *European Heart Journal-Case Reports*. 2021 Mar;5(3): ytab088.
 - 33 Duraisamy ka. Ebstein's anomaly in congenital rubella syndrome-a rare association-a case report. *university journal of medicine and medical specialities*. 2019 feb 9;5(1).
 - 34 Phi K, Martin DP, Beebe A, Klamar J, Tobias JD. Anesthetic Care During Posterior Spinal Fusion in an Adolescent with Ebstein's Anomaly. *Journal of Medical Cases*. 2020 Mar 26;11(3):68-72.